



PATIENT

Murphy Karri

SPECIES

Canine

BREED

Golden Retriever

SEX

MN

AGE

8

WEIGHT

75.6

INTERPRETED BY

R. McKenzie Daniel,
DVM, DABVP
(Canine and Feline)

IMAGING PERFORMED BY

Jenn

HOSPITAL NAME

Rockaway Animal
Hospital

REFERRING VET

Dr Maniar

INVOICE 24090

DATE
03/03/2026

PRESENTING CLINICAL SIGNS

re check from 3/2 vomited bile 2 times over night

ULTRASONOGRAPHIC EXAMINATION OF THE ABDOMEN

Urinary System

The urinary bladder, trigone, cystourethral junction, and visible pelvic urethra to a depth of 4 cm exhibited normal thickness and tone. Anechoic urine was present in the lumen with no evidence of urine/lumen sediment, mineral, or calculi. The ureteral papillae were normal. The ureters were not visible which is normal. No evidence of inflammatory or neoplastic changes was noted.

Normal size and margination were present in the kidneys. A normal 1:3 cortex / medulla ratio and normal corticomedullary definition were maintained. The echogenicity of the cortex was similar to or slightly less than normal liver parenchyma while the medulla echogenicity was hypoechoic to the cortex with no evidence of pelvic dilation. The left kidney measured 6.0 cm in length. The right kidney measured 6.5 cm in length.

The area of the aortic trifurcation was free of pathology.

The residual prostate appeared normal and free of pathology.

Adrenal Glands

No obvious pathology in the area of the left or right adrenal glands.

Spleen

The spleen exhibited a finely textured and homogenous parenchyma which was hyperechoic to the liver and renal cortical parenchyma. The capsule was smooth and regular without apparent expansion. The splenic vasculature at the hilus was normal in volume with no evidence of congestion or thrombosis. Acute to chronic inflammatory, neoplastic, or benign parenchyma changes were not noted.

Liver/Gallbladder

The liver was subjectively normal in size, structure, and contour. The liver parenchyma was uniform and hypoechoic to the spleen with a mild coarse echotexture. Normal vascular volume. The hepatic and portal vasculature were normal in appearance without signs of congestion. The gallbladder was non-distended in size with thin walls and primarily anechoic luminal content. The cystic and common bile ducts were normal.

Gastrointestinal

The stomach presented intact visible wall. The stomach contained lumen gas with a persistent to mildly reduced amount of progressively shadowing content measuring ~ 2.5 cm in diameter. No evidence of obstruction to pyloric outflow.

The small intestine presented intact wall layering with 1:3 muscularis/mucosa ratio. The lumen of the small intestine was empty with no signs of mechanical/metabolic ileus, obstruction or foreign material.

Normal visible colon wall layers were present with apparent formed feces in lumen.

Pancreas



PATIENT

Murphy Karri

The parenchyma of the left limb, body and right limb of the pancreas presented isoechoic to the adjacent omental fat. A normal curvilinear capsule contour of the pancreas was present. The visible pancreatic duct was normal. No signs of active inflammation or neoplastic disease was evident.

SPECIES

Canine

Free Abdomen

No omental masses, overt lymphadenopathy or peritoneal effusion was present.

BREED

Golden Retriever

ULTRASONOGRAPHIC FINDINGS

Primary

- Non-distended stomach with lumen gas and persistent progressively shadowing content
- Normal empty small intestine

SEX

MN

INTERPRETATION OF THE FINDINGS & FURTHER RECOMMENDATIONS

AGE

8

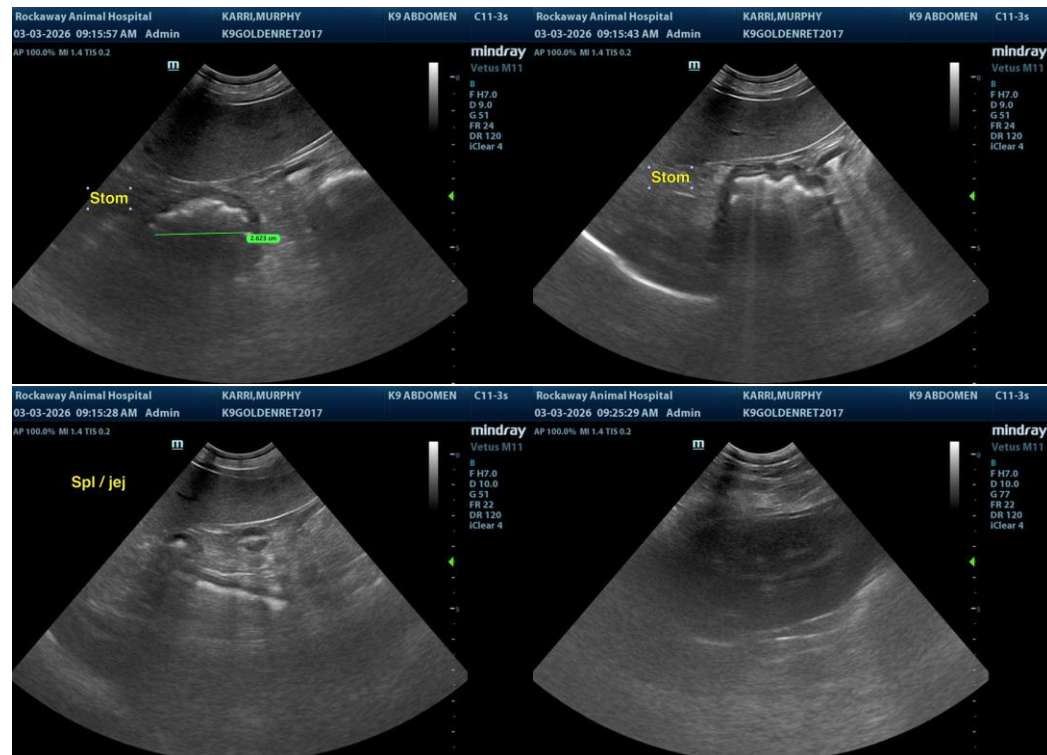
The persistent progressively shadowing gastric content appears slightly reduced compared to the previous study yet could indicate persistent gastric foreign material given patient history. No evidence of small intestinal mechanical obstruction or additional shadowing intestinal content. If available, gastric endoscopy would be ideal for further clarification of the gastric content. Otherwise, if the patient is stable, considerations may include continued sonographic monitoring with gastrointestinal support or exploratory laparotomy with gastric evacuation via gastrotomy if persistent or progressive gastrointestinal signs.

WEIGHT

75.6

INTERPRETED BY

R. McKenzie Daniel,
DVM, DABVP
(Canine and Feline)



IMAGING PERFORMED BY

Jenn

HOSPITAL NAME

Rockaway Animal
Hospital

REFERRING VET

Dr Maniar

INVOICE

24090

DATE

03/03/2026



PATIENT

Murphy Karri

SPECIES

Canine

BREED

Golden Retriever

SEX

MN

AGE

8

WEIGHT

75.6

INTERPRETED BY

R. McKenzie Daniel,
DVM, DABVP
(Canine and Feline)

IMAGING PERFORMED BY

Jenn

HOSPITAL NAME

Rockaway Animal
Hospital

REFERRING VET

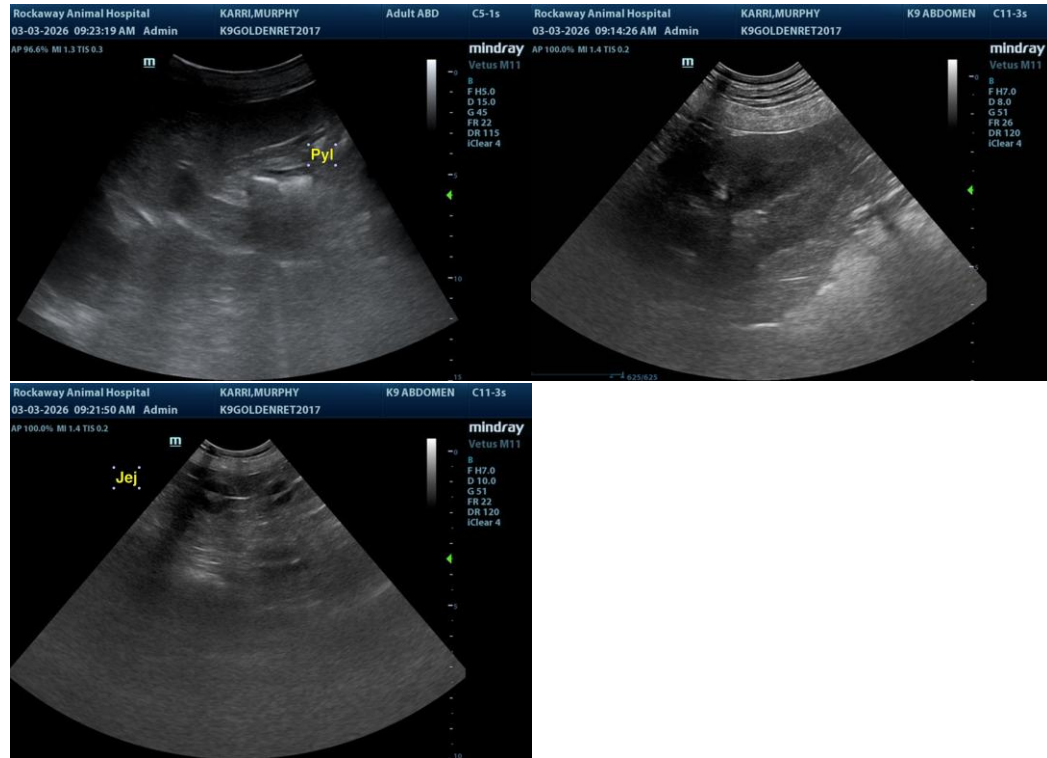
Dr Maniar

INVOICE

24090

DATE

03/03/2026



The information and recommendations provided are based on the images presented by the referring veterinarian/sonographer. No evaluation can be communicated regarding pathology that was not visible in the image/video clips provided.

Thank you for this referral. If the clinical or image interpretation does not parallel your findings or if I can be of any further assistance, please contact me.

R. McKenzie Daniel, DVM, DABVP (Canine/Feline Practice)
info@sonopath.com